

The Use of a Lyophilized Dehydrated Complete Human Placental Membrane (dCHPM) Allograft for Wound Bed Preparation in a Trauma Induced Wound

AS DESCRIBED BY DR. MOHAMMAD SHARIF, DR. MONICA DONTAMSETTI, DR. ANILA RAFIQ | ATLANTA, GA

INTRODUCTION

As of October 2019, approximately three million people annually are injured in motor vehicle accidents.¹ The resulting soft tissue injuries can range from whiplash to dermal lacerations, like scrapes and cuts. Among the lacerating wounds, full-thickness wounds occur when the wound extends through the epidermis and dermis, reaching the subcutaneous tissue. Traumatic lower extremity injuries sustained from road traffic accidents may affect vascular processes, creating an ischemic environment which can lead to amputation.² Amputation frequently results in lifelong physical, emotional, and economic consequences. The Lower Extremity Assessment Project, a multicenter study of severe lower extremity trauma, reported that two years post-injury only 54.4% of patients who were working prior to the injury had returned to work.³

While split-thickness skin grafts (STSG) are considered the gold standard of wound care, graft failure is not an uncommon complication. In a three year study completed by Georgetown University Hospital, there was a reported STSG failure rate of 31.8%.⁴ Factors affecting the autograft success include wound bed preparation, patient demographics, comorbidities, and surgical dressing used after the STSG placement.⁴ The ideal wound bed conditions for a successful take of a STSG to treat a chronic wound include; the presence of vascularized granulation tissue, tissue coverage of tendon and bones, minimal exudate, and a lack of necrotic tissue.⁵

The benefits of placental membrane allografts as a wound covering have been acknowledged and explored since the early twentieth century.⁶ As tissue processing techniques improved, placental tissue was commercialized for a variety of applications; one of the most common being wound care.⁶

Placental membranes are commonly used as a wound covering due to native structural components that include collagens, fibronectin, and laminin.⁶

Previously, commercially available membranes have retained only one or two of the native placental

membrane layers. StimLabs' lyophilized dCHPM is the first commercially available allograft to retain all three native layers; the amnion, intermediate layer, and chorion.⁷ While many of the target molecules in native placental membrane can be found within all layers of the tissue, specific structural components, like collagen and glycosaminoglycans, are found heavily concentrated in the intermediate layer.⁷

MEDICAL HISTORY AND PRIOR TREATMENT

A healthy 32-year-old male presented with severe left foot injury secondary to a car accident. The patient was taken to another local facility where a partial first ray amputation and debridement was performed.

INITIAL PRESENTATION AT THE TRAINING FACILITY

Six weeks post first ray amputation, the patient presented at the Village Podiatry facility, where he complained of pain and drainage to his foot. Upon initial examination, a large necrotic wound was noted on his dorsal foot with a cyanotic second toe. (Figure 1.)

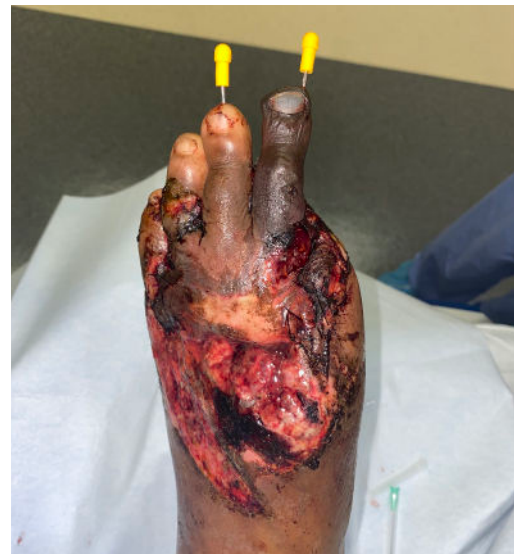

Figure 1. Initial presentation in wound facility.

The patient was treated with serial debridement and a second toe amputation.

TREATMENT

WOUND PREPARATION AND ALLOGRAFT APPLICATION

During the third Village Podiatry facility visit, the patient underwent wound bed preparation for a STSG from the left thigh.

The wound was debrided using sharp debridement techniques. The wound measured 10 cm x 8 cm with 40% granulation tissue coverage of the wound bed. Exposed tendon was noted in the debrided wound. (Figure 2a.)

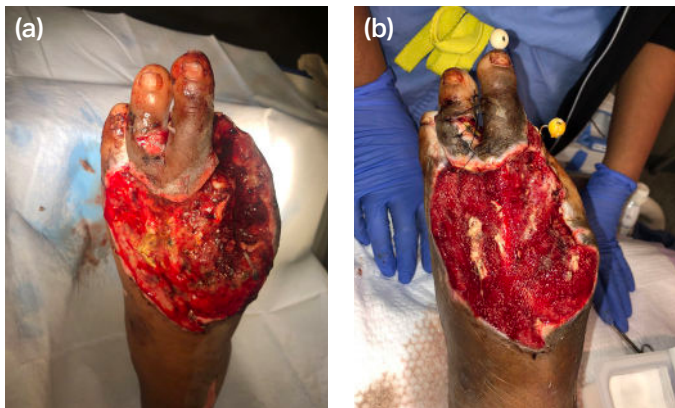


Figure 2. (a) Post debridement and amputation with 40% granulation. Pre-lyophilized dCHPM application. (b) One week after the allograft application, post debridement with 90% granulation.

Three 6x8 cm lyophilized dCHPM allografts were fenestrated and placed on the wound bed with allograft contact on the wound margins. Following a non-adherent contact layer, a negative pressure wound vacuum was applied. The physician rated the ease of allograft application and product handling as excellent.⁸ The allograft was noted to be able to withstand suturing and wrapping and function well under a negative pressure wound vacuum.⁸

ALLOGRAFT RESULTS AND STSG PROCEDURE

One week following the lyophilized dCHPM application, the patient returned for the STSG procedure. Prior to debridement, the allograft remnants were visible in the wound bed. Following the debridement of allograft remnants and necrotic tissue, the wound showed signs of closure. The wound size had decreased to 9 cm x 7 cm with significant improvement of granulation tissue, with documented increase from 40% to 90% wound bed coverage. (Figure 2b.) A STSG procedure was performed.

FOLLOW UP

Patient had full take of the STSG and saw complete resolution of the wound within three weeks of the STSG application. (Figure 3.)

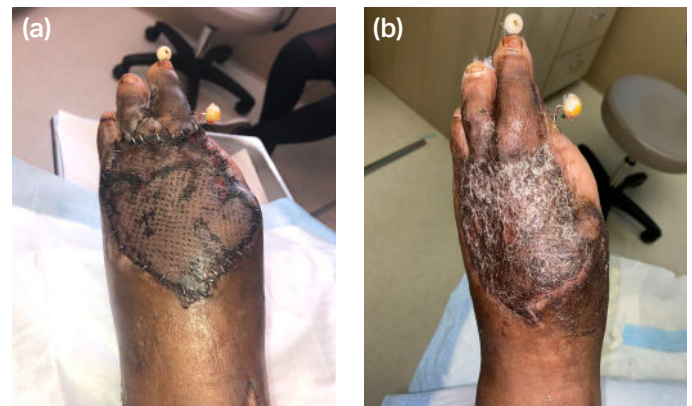

Figure 3. (a) Post STSG application. (b) At 3 week follow up with complete take of STSG.

For more information, visit stimlabs.com

1. Centers for Disease Control and Prevention. (201). Motor Vehicle Injury. <https://www.cdc.gov/publichealthgateway/didyouknow/topic/vehicle.html> 2. Perkins, Z. B., De'Ath, H. D., Aylwin, C., Brohi, K., Walsh, M., & Tai, N. R. (2012). Epidemiology and outcome of vascular trauma at a British Major Trauma Centre. *European Journal of Vascular and Endovascular Surgery : The Official Journal of the European Society for Vascular Surgery*, 44(2), 203–209. 3. MacKenzie, E. J., Bosse, M. J., Castillo, R. C., Smith, D. G., Webb, L. X., Kellam, J. F., Burgess, A. R., Swiontkowski, M. F., Sanders, R. W., Jones, A. L., McAndrew, M. P., Patterson, B. M., Trivison, T. G., & McCarthy, M. L. (2004). Functional outcomes following trauma-related lower-extremity amputation. *The Journal of Bone and Joint Surgery. American volume*, 86(8), 1636–1645. 4. Turissini JD, Elmarsafi T, Evans KK, Kim PJ. (2019) Major Risk Factors Contributing to Split Thickness Skin Graft Failure. *Georgetown Medical Review*, 3(1). 5. Donegan, R. J., Schmidt, B. M., & Blume, P. A. (2014). An overview of factors maximizing successful split-thickness skin grafting in diabetic wounds. *Diabetic Foot & Ankle*, 5(1), 24769. 6. Silini, A. R., Cargnoni, A., Magatti, M., Pianta, S., & Parolini, O. (2015). The Long Path of Human Placenta, and Its Derivatives, in Regenerative Medicine. *Frontiers in Bioengineering and Biotechnology*, 3. 7. Roy, A., & Griffiths, S. (2020). Intermediate layer contribution in placental membrane allografts. *Journal of Tissue Engineering and Regenerative Medicine*, 14(8), 1126–1135. 8. Data on file.